

## A Variation In Origin And Branching Pattern Of Medial And Lateral Circumflex Femoral Artery – A Rare Case Report

Dr Ashish Radke MD<sup>1</sup>, Dr Yogesh S Ganorkar MD<sup>1</sup>, Dr Rakesh kumar Jha<sup>1</sup>  
Indira Gandhi Govt. Medical College, Nagpur

**Abstract :** Profunda femoris artery is a deep and largest branch of femoral artery. Profunda femoris artery gives off the medial and lateral circumflex femoral artery. Femoral nerve divided into anterior and posterior division by lateral circumflex femoral artery. Profunda femoris artery, medial and lateral circumflex femoral artery are used extensively in different diagnostic and therapeutic intervention. Knowledge of anatomical variation helps to prevent the iatrogenic complication. In present case study, both medial and lateral circumflex femoral artery of right limb are directly arise from right femoral artery instead of profunda femoris artery. Variation is found during the routine dissection. Femoral artery and its branches on left side are normal in course. Knowledge of these variation can be great help to surgeons in reducing the chances of intraoperative and post operative complication.

**Keyword:** Femoral artery (FA), Profunda femoris artery (PFA), Medial circumflex femoral artery (MCFA), Lateral circumflex femoral artery (LCFA)

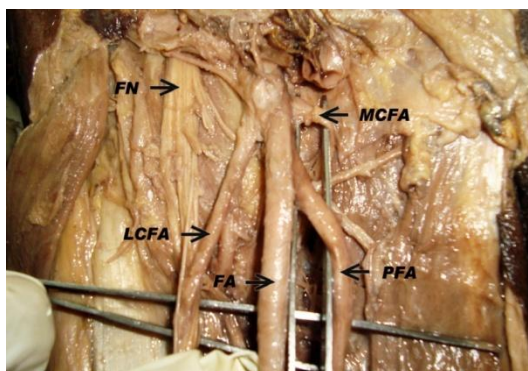
### I. Introduction

Profunda femoris artery is larger branch of femoral artery. It gives off medial and lateral circumflex femoral artery. LCFA is laterally running branch given off near the root of Profunda femoris artery. It passes between anterior and posterior division of femoral nerve and get divided into ascending, descending and transverse branch.

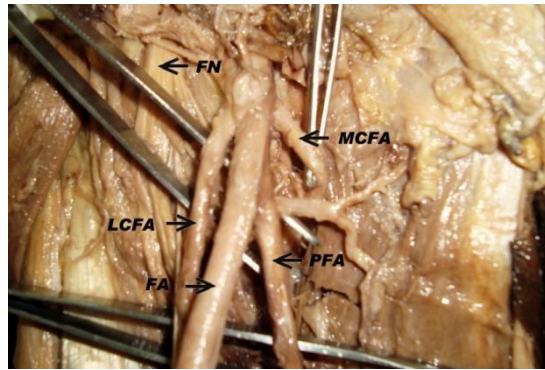
MCFA is given off from posteromedial aspect of Profunda femoris artery. It gives off transverse and ascending branches at upper margin of adductor magnus and anastomose with LCFA. Variation in origin of branches have been reported earlier. Knowledge of this variation is important for academic and clinical purposes.

### II. Case Report

During the routine dissection of right limb of 70 yr old male cadaver in department of anatomy, IGGMC, Nagpur, unusual origin and branching pattern of MCFA and LCFA of right lower limb was observed. The MCFA and LCFA was found to be originating from right Femoral artery instead of Profunda femoris artery.



The origin is about 3 cm from midinguinal point. Diameter of the LCFA was 0.3 cm and that of MCFA was about 0.2 cm. The LCFA gives ascending, descending and transverse branches. MCFA goes on medial and posterior aspect and gives transverse and ascending branches. MCFA and LCFA originate very close to origin of Profunda femoris artery. The LCFA divide the Femoral nerve into their anterior and posterior division. The LCFA and MCFA of left limb having no variation and having normal course.



### III. Discussion

MCFA and LCFA are branches of Profunda femoris artery. Several variation of origin of both the arteries have been reported earlier. These variations are important in various surgical procedures of Femoral region.

In the present case, we report that LCFA and MCFA was originating directly from Femoral artery instead of Profunda femoris artery. LCFA is laterally running branch given off near the root of profunda femoris artery and MCFA is another branch given off from medial and posterior aspect near the root of Profunda femoris artery. Their origin about 3 cm from the midinguinal point and proximal shift of level of separation of profunda femoris artery from right femoral artery was observed.

The common trunk of Profunda femoris artery, LCFA and MCFA was observed by UZel et. Al<sup>1</sup>(2008) in 0.9% cases. They stated that, when MCFA arise from Femoral artery, mean distance from midinguinal point is 4.2 cm and when it arises from Profunda femoris artery, the mean distance from midinguinal point is 5.8 cm.

Prakash et. Al<sup>2</sup>(2010) concluded that circumflex branches of Profunda femoris artery branch directly from Femoral artery, when it associated with lower level of separation of Profunda femoris artery from Femoral artery.

Hussain T et. Al<sup>3</sup>(2007) has also reported the origin of MCFA and LCFA from Femoral artery. Fischer(1827) reported direct origin of LCFA and MCFA from External Iliac in 2% cases. Reid (1836) also reported origin of MCFA and LCFA from Inferior epigastric artery in 7% cases.

Daksha dixit et. al (2010)<sup>4</sup> also stated that origin of MCFA and LCFA arise directly from Femoral artery associated with distal shift of level of separation of the Profundafemoris artery from Femoral artery. Dixit DP (2001) et. Al<sup>5</sup> found in his study that MCFA has more variable origin from Femoral artery than LCFA. Clark S.M. et.al (1993)<sup>6</sup> also observed origin of LCFA and MCFA from Femoral artery in 2.1% cases. LCFA and MCFA was originating from Femoral artery and was found to be branching into its respective branches. This was found rare in literature and Present case is the first to report it.

### IV. Conclusion

The present case provide information of the rare occurrence of origin of MCFA and LCFA from Femoral artery. This variation is significant for interventional radiological procedure like angiography, color doppler and in plastic and reconstructive surgery. The present case is of high significance to minimise the complication in hip joint replacement, catheterisation, Repair of Femoral hernia, surgical intervention for embolism, angiography, vascular reconstructive surgeries performed in Femoral triangle.

Knowledge of the origin and branching pattern is essential in enhancing precision and decreasing morbidity related to surgical and interventional procedure. So iatrogenic injury can be avoided with the knowledge of anatomical variation.

### References

- [1]. UZel M, Tangelo E et al, An anatomical study of the origin of lateral circumflex femoral artery in Turkish population 2008;67(4);226-230.
- [2]. Prakash, Kumari J et al, Variation in origin of the profunda femoris, medial and lateral circumflex femoral artery; 2010;51:167-170.
- [3]. Hussain T, Bapist M, Anatomical variation of the profunda femoris artery and its branches; 2007;14(3);523-527.
- [4]. Daksha Dixit et al, A study of variation in the origin of profunda femoris artery and its circumflex branches; 2011;2(4);1084-1089.
- [5]. Dixit DP, Mehata LA et al, Variation in the origin and course of profunda femoris artery; 2001;50(1);6-7.
- [6]. Clark SM, Colborn GL et al, The medial femoral artery; its clinical anatomy and nomenclature; 6;94-105.